

Dear Client,

This is your second opinion report.

### **How to read the report**

1. Always consult your findings with your doctor.
2. Please bear in mind that the report is based only on the information you provide and Diagnose.me specialists will not have the opportunity to examine you personally.
3. If you or your doctor have any follow up questions related to this report, you can ask your chosen specialist follow up questions for 10 days following the delivery of this report.
4. For a more in-depth discussion, your selected specialist may offer a video consultation to discuss your questions. Please note that there is an extra fee for this service.
5. Please feel free to contact us anytime. We are here to support you on your way to recovery.

We wish you a quick recovery and hope that this report will contribute to finding the correct diagnosis and effective treatment,

Your Diagnose.me team

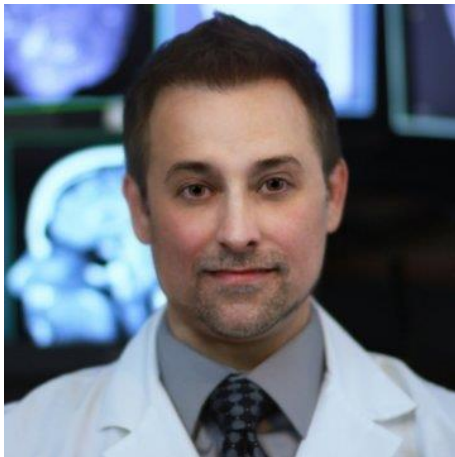# Diagnose.me Case Report

Case number [REDACTED]

Created on [REDACTED]

## Specialist

**Daniel Saurborn**



Profile link:

<https://www.diagnose.me/en/specialists/daniel-saurborn>

## 1. Clinical information

Gender [REDACTED]

Year of birth [REDACTED]

## 2. Details of examinations

Medical data	Description	Date of exam
[REDACTED]	[REDACTED]	[REDACTED]

### 3. Patient's question

Short term memory loss; diabetes are major issues. Doctor ordered an MRI a couple of weeks ago because patient was experiencing really bad headaches. Patient was diagnosed in [REDACTED] as early onset Alzheimers, but he changed doctors two years ago and was told he would have been in a nursing home by then if he had ALZ and took him off meds. The new MRI was declared "nothing new; stay in touch with your neurologist". I (his wife) feel there is something in this new MRI they overlooked and want a second opinion.

### 4. Description of findings

**T1 and T2 sequences:** There is mild-moderate brain atrophy which produces some prominence of the ventricular system and the sulci. The posterior horn of the right lateral ventricle is slightly more dilated than left which may indicate asymmetric atrophy of the right parietal-occipital lobe compared to the left. I see no evidence of blood in the brain, or brain tumor.

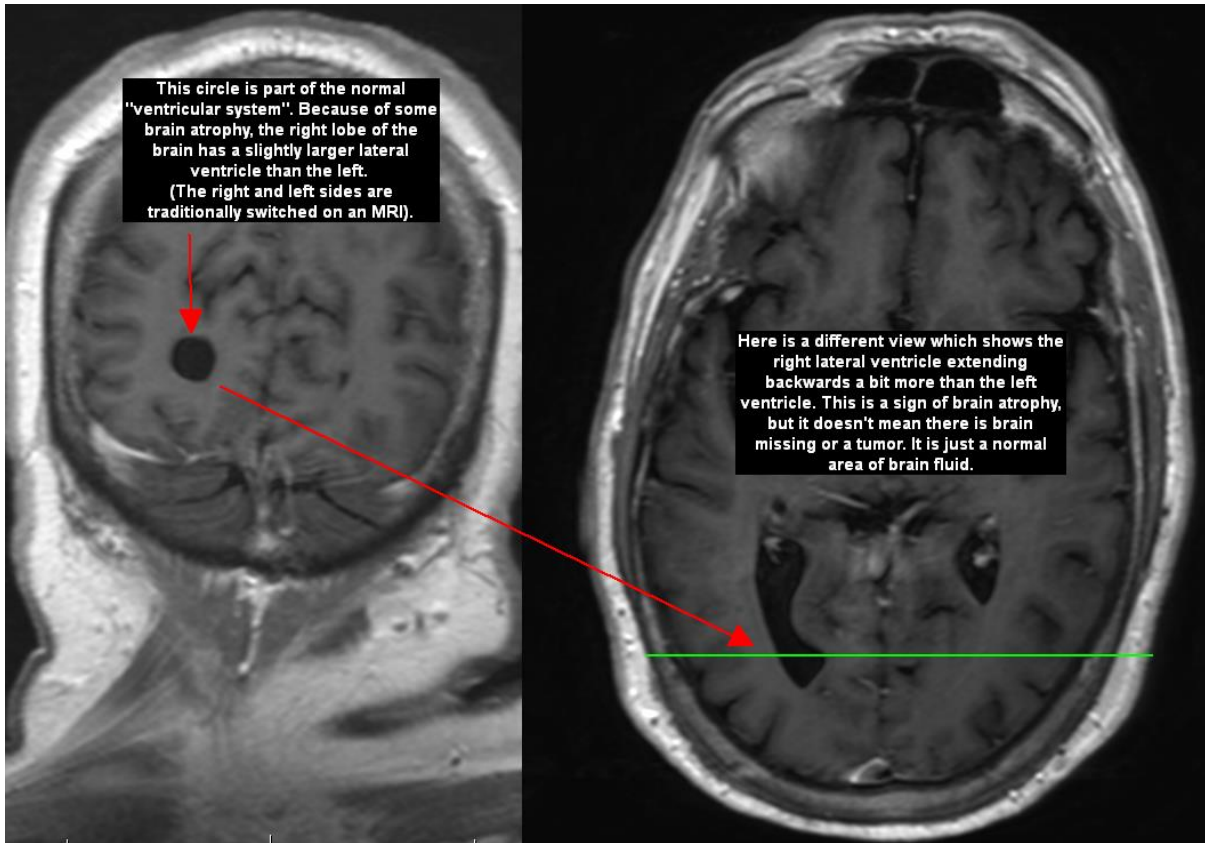
**FLAIR sequences:** Scattered areas of white matter hyperintensity within the deep periventricular regions, often seen in patients with small vessel ischemic disease.

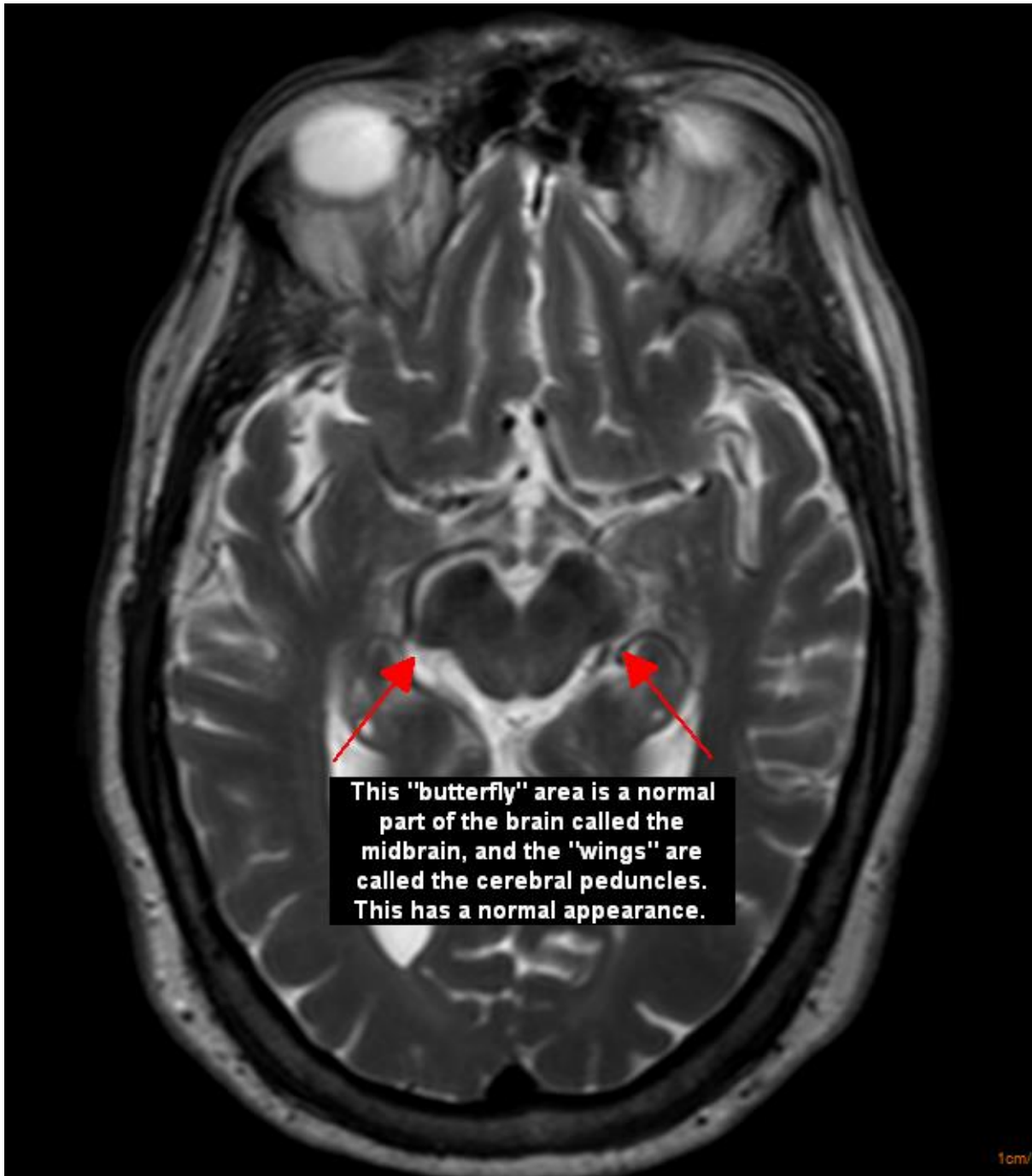**Vascular flow voids:** The basilar artery is somewhat prominent and tortuous, but without aneurysm.

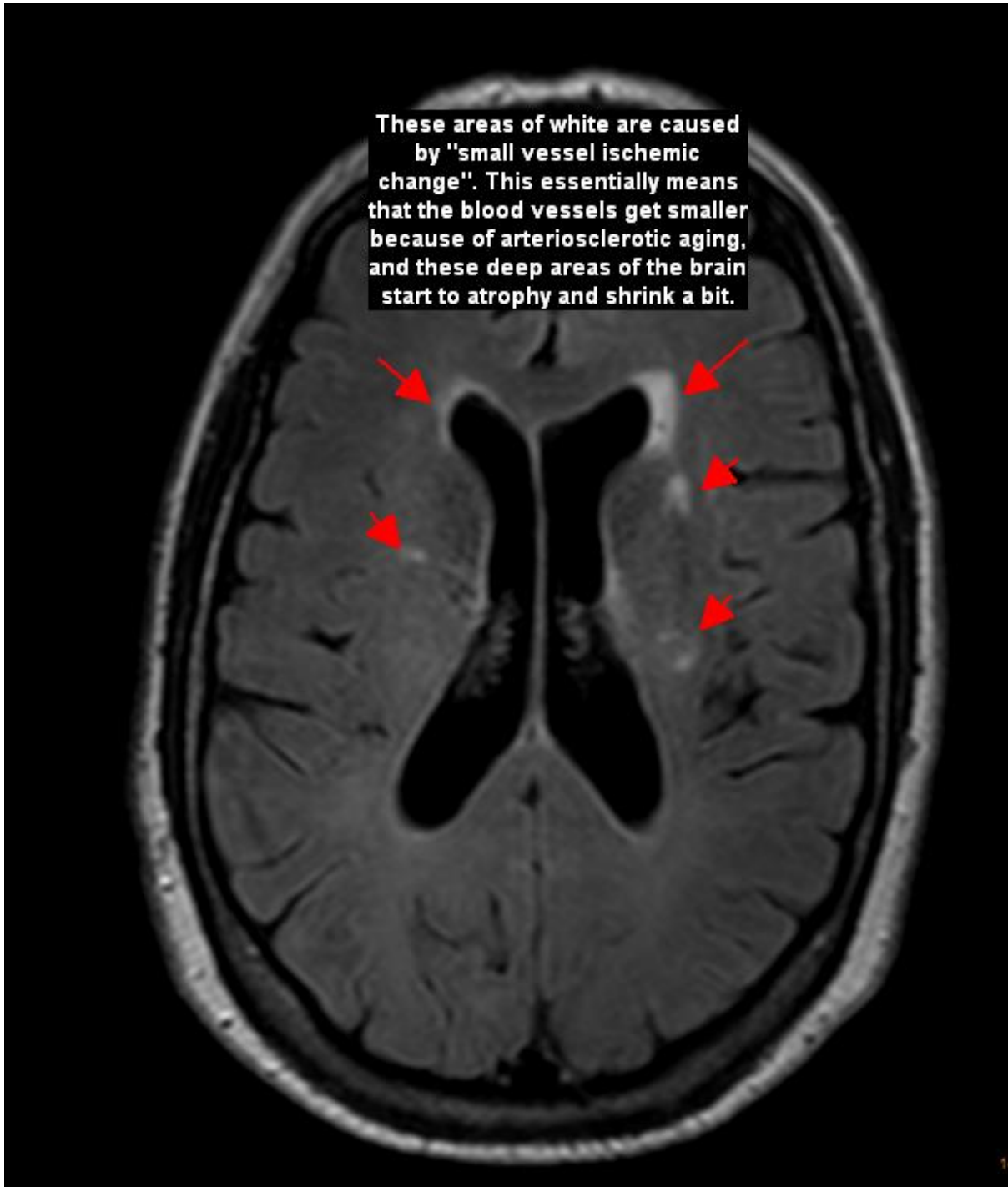
**Midline:** Pituitary normal size. Brain stem and corpus callosum appear normal.

**Sinuses:** There has been sinus surgery with removal of the middle turbinates. There is a small amount of mucosal thickening in the right axillary sinus.

**Diffusion Imaging:** No regions of abnormal hyperintensity to suggest acute stroke.







1. Generalized atrophy of the brain, with evidence of small vessel ischemic changes in the deep white matter, consistent with the stated history of diabetes, which can produce premature aging of the brain.
2. I do not see any specific evidence of Alzheimer's, brain bleeding, acute stroke, or brain tumor on the current exam

## 5. Conclusions and Advice

1. I do not see anything on the current exam which would be responsible for increasing headaches, unless his sinuses were becoming symptomatic. There is a little bit of fluid in the right maxillary sinus, but it does not appear to be enough to cause a sinus headache. I also don't see any evidence of blood or tumor, which can sometimes cause headaches, and that is a good thing. I would consult with his neurologist again, or with a headache expert specifically, if the headaches persist or get worse.

2. Usually, patients with Alzheimer's disease will have more atrophy in the middle of the brain (temporal lobes) than other regions. The atrophy on this MRI appears relatively diffuse and the same from front to back, so Alzheimer's seems less likely. Because of the history of diabetes, his dementia may be due to more advanced vascular disease caused by diabetes. If you and his doctors would like a more confident exclusion of Alzheimer's, though, they could order what is called a PET scan of the brain using an Alzheimer's specific tracer, which has been shown to diagnose Alzheimer's better than MRI. I am not certain that this is necessary, unless everyone has a very strong suspicion that Alzheimer's is the cause.

Thank you very much for the opportunity to assist you in your husband's medical care.

Please let me know if there is anything else I can do to help you.

Sincerely,

Dr. Daniel Saurborn, MD

## Patient feedback

Thank you Dr. Saurborn! You answered all my questions and in such a clear, easy-to-understand way that I was immediately comforted. I've never had a doctor explain test results so nicely before in my ■ years!

I'm so happy I got a second opinion because I can now let go of the fears hounding me after comparing MRI results to images on Google etc. We will continue with visits to the neurologist and endocrinologist for treatments.

You and Diagnose.Me are a blessing! I 100% recommend you to anyone needing a second opinion of their images.