

Dear Client,

This is your second opinion report.

How to read the report

1. Always consult your findings with your doctor.
2. Please bear in mind that the report is based only on the information you provide and Diagnose.me specialists will not have the opportunity to examine you personally.
3. If you or your doctor have any follow up questions related to this report, you can ask your chosen specialist follow up questions for 10 days following the delivery of this report.
4. For a more in-depth discussion, your selected specialist may offer a video consultation to discuss your questions. Please note that there is an extra fee for this service.
5. Please feel free to contact us anytime. We are here to support you on your way to recovery.

We wish you a quick recovery and hope that this report will contribute to finding the correct diagnosis and effective treatment,

Your Diagnose.me team

Diagnose.me Case Report

Case number [REDACTED]

Created on [REDACTED]

Specialist

Andrei E. Tsoriev



Profile link:

<https://www.diagnose.me/en/radiologists/andrei-tsoriev>

1. Clinical information

Gender [REDACTED]

Year of birth [REDACTED]

2. Details of examinations

Medical data	Description	Date of exam
[REDACTED]	[REDACTED]	[REDACTED]

3. Patient's question

Original language:

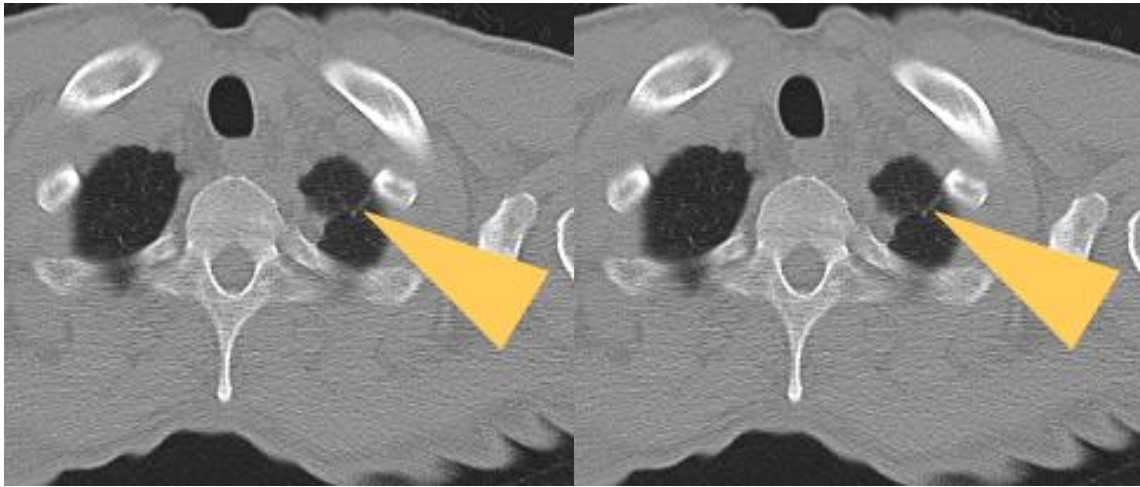
Vo [REDACTED] som mal tupú bolesť v oblasti žalúdka, absolvoval som vyšetrenie-gastroskopia. Po 10-tich dňoch som volal o výsledok, no ešte ho nemali, ale žalúdok ma už prestal bolieť, tak som to nechal tak. Lekár mi ale predpísal tabletky, ktoré som ale nebral, lebo ta slabá bolesť odišla. V lete na dovolenke sa to znovu ozvalo a po príchode domov som ichned volal na ambulanciu, kde som absolvoval februárové vyšetrenie a tam mi oznámili, že výsledok je negatívny a až potom som vybral tie malé tabletky. No v novembri sa žalúdok opäť ozval, šiel som na vyšetrenie a [REDACTED] mi gastroenteologička oznámila pozitívny výsledok. [REDACTED] som bol operovaný a na chemoterapiu som nastúpil [REDACTED], [REDACTED] mi urobili CT vyšetrenie a od [REDACTED] mi nasadili 5 dni chemoterapiu, potom som mal pauzu a následne na druhý cyklus chemoterapie som nastúpil [REDACTED], kde som vybral 5 davok a zároveň od [REDACTED] dostávam každý deň radioterapiu. Radioterapiu mam dostať 25 krát. Dalsie informacie su v prilozenej Prepustacej sprave. Chcem sa opytat na zhodnotenie predpisanej liečby (chemo+radioterapia) a operacie a tiež, ci sa na snimke nachadzaju metastazy. Aku dalsiu liečbu odporucate? Ake su prognozy pri tejto diagnoze?

English Translation

In [REDACTED] I had a dull pain in the stomach, I underwent an examination- gastroscopy. After 10 days I called for the result, but wasn't ready, but because my stomach stopped hurting, I let it be. The doctor prescribed me pills that I didn't take because the mild pain was gone. During the summer holidays it happened again and upon arrival at home I immediately called the out patient department, where I underwent the February exam and there I was told that the result is negative, and only then I picked up the small pills. But in November, the stomach pain came back, I went for an examination and on the [REDACTED] the gastroenterologist announced a positive result. On [REDACTED] I was operated on [REDACTED] I started chemotherapy, [REDACTED] I did a CT scan and from [REDACTED] I was put on chemotherapy for five days, then I had a break and then the second cycle of chemotherapy on [REDACTED], where I received 5 rounds, and from [REDACTED] I am simultaneously receiving daily radiotherapy. I am supposed to receive radiotherapy 25 times. Additional information is in the attached discharge letter. I want to ask for an assessment of the prescribed treatment (chemo-radiotherapy) and operations and also whether there are metastases on the images. What further treatment do you recommend? What is the prognosis for this diagnosis?

4. Description of findings

Several small foci of lungs apical fibrosis seen:



No enlarged lymph nodes. No pleural mass and/or effusion. Osteocartilaginous degenerative changes seen in spine, other visible joints, no other relevant changes seen. Thoracic vessels normal. Soft tissues of thoracic wall normal.

Abdomen

Liver: Enlarged, with rounded right lobe margin, density and enhancement – normal, no focal changes. Portal vein diameter 19,7 mm, splenic vein diameter – 10,5 mm (both distended).

Bile ducts: Normal. Common bile duct diameter is 6,5 mm.

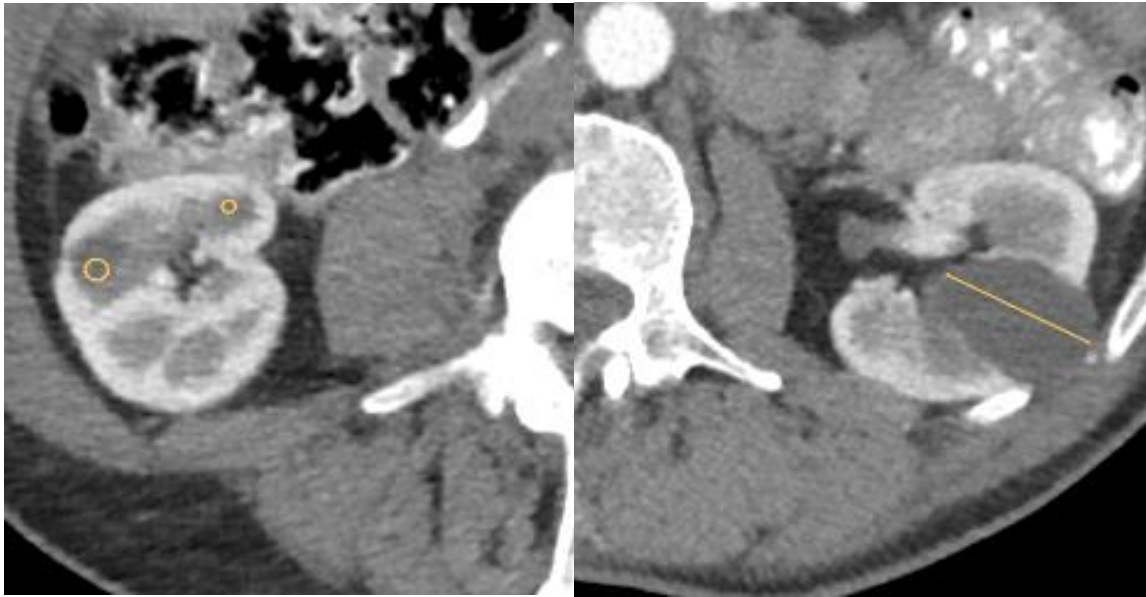
Gallbladder: No calcified gallstones. Normal caliber wall.

Pancreas: Normal. Uniformly enhancing, no pancreatic duct distension.

Spleen: Normal. Splenic index – 396 (normal up to 480).

Adrenals: Normal.

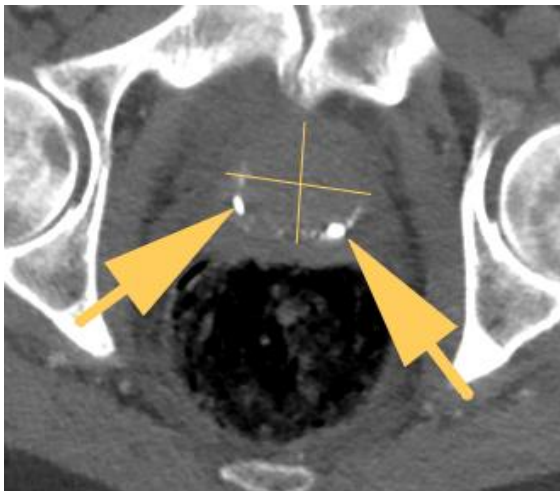
Kidneys: Cysts 10 and 7 mm in right kidney with intraparenchymal location, 34 mm in left kidney with subcapsular location. Left larger cyst doesn't enhance with contrast, right cysts visually also doesn't enhance, measurement is impossible due to thick slices (3 mm) and small cysts sizes. Kidneys are functioning, collecting systems and ureters of normal sizes.



Stomach is absent (removed). Esophagoenteroanastomosis is normal.

Pelvis

Reproductive organs: Prostate sized 35x43x42 mm (volume ~ 31 ml), multiple confluent calcifications in the peripheral zone. Seminal vesicles normal.



Ureters normal.

Bladder: Normal.

Bowel: Normal caliber. Lumen is uniformly filled with contrast, no mass lesions.

Abdominal and pelvic lymph nodes: No enlarged lymph nodes.

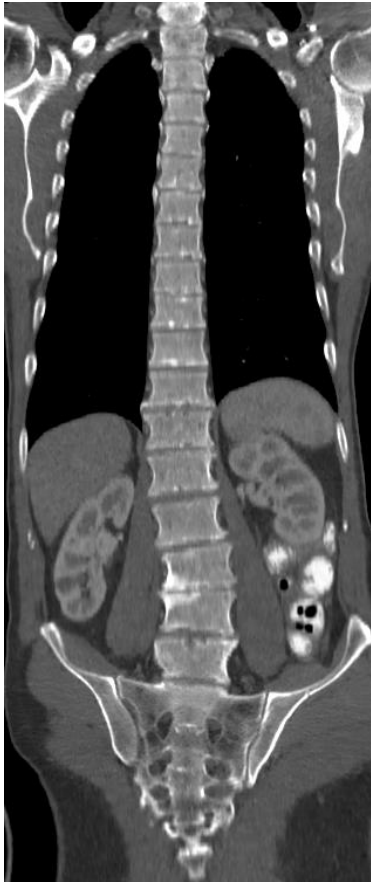Peritoneum: [No ascites or free air; no fluid collection. No nodularity.

Vessels: No stenotic/atherosclerotic changes.

Retroperitoneum: Normal.

Abdominal wall: Postsurgery scar in the midline.

Bones: Thoracolumbar spine degenerative changes Pfirrmann grades 2-3-4 , S-type scoliosis of lower thoracic and lumbar spine:



Postsurgery (gastrectomy with esophagojejunoanastomosis) state, no recurrence and no suspicious lymph nodes found.

Small subpleural fibrotic changes in upper lungs of no clinical significance. Hepatomegaly with portal and splenic vein distension: chronic liver disease? Chemotherapy hepatotoxicity? Renal simple cysts of no clinical significance. Prostatic calcifications as a result of ageing and/or chronic prostatitis: have no clinical significance in absence of symptoms. Spine and joints degenerative changes as a result of ageing or/and overload, repeated small trauma. Spinal scoliosis.

5. Conclusions and Advice

Small (smaller than 10 mm) lymph nodes usually considered being benign, but their exact condition is unknown, in some cases PET-CT may help clarify the diagnosis of absence/presence of nodal involvement. Discuss with your oncologist the need and possibility of PET-CT. It should be remembered that mucinous cancers are not seen in PET-CT.

Further and follow up radiological investigations should be carried out in Patients who are candidates for further chemo- or radiotherapy for assessment their prechemotherapy state and to evaluate treatment response and/or recurrence in case of suspicion.

The treatment you have is modern one and combined therapy is the most appropriate treatment in your case, particular details of the treatment are beyond the radiologist's competency.

When talking about prognosis no one can tell the prognosis in your particular case, but oncologists operate with statistics, which say the following:
«The overall 5-year relative survival rate of all people with stomach cancer in the United States is about 29%. The 5-year relative survival rate compares the observed survival of people with stomach cancer to that expected for people without stomach cancer. The stage IIIa 5-year survival rate of people with stomach cancer is 20%.»

Kind regards,
Dr. Andrej Tsoriev

Patient feedback

Thank you very much, Dr. Tsoriev. Our family wanted to get a consultation about our uncle's case. We wanted to make sure, that nothing important has been overlooked and that the treatment of his stomach cancer is suitable. We liked your thorough approach, attention to detail and clarity. We highly recommend you as a doctor. We now know that although our uncle has a serious diagnosis, things are relatively OK and his treatment is suitable and modern.